

No. 32

Ob/Gyn

Instruments

29 pages



Done by: Hejaz Sp. 424

Female Students of 424 King Saud University Year 2007 – 2008

بسم الله الرحمن الرحيم

كان الـ **Session** الخاص بنا لموضوع الـ **Instrument** سيء للغاية!...
وانتهى الأمر على لعبة (التعارف) ،، مع لمحات بسيطة للاستخدامات
وموانعها

استعنا في هذه المذكرة بعد الله سبحانه على **Draft** كان قد كُتب مسبقاً من
طلاب جامعة الملك عبدالعزيز
وأضفنا عليه العديد من التعديلات والأدوات التي لم تذكر من قبل

لا نستطيع الجزم أن المذكرة كالأملة ! لكن بحول الله
كل ما ذكر واستطعنا الوصول إليه.. بذلنا الجهد في ترتيب معلوماته
وتسهيلها



تمنياتنا لكم بالتوفيق،، ودعواتكم

Hejaz Sp. 424

I. Gynecological Instruments

Vaginal Specula

(1) *Cusco's non-fenestrated bivalvular self-retaining vaginal speculum*

Indications:

1. It is used during clinical examination to expose the cervix and vaginal walls.
2. It allows the application of local treatment to the cervix.
3. It allows introduction of the uterine sound, insertion of IUD, performing hysterosalpinogography, taking premenstrual endometrial biopsy, surface biopsy scraping of the cervix ... etc.
4. It is used to expose the two sides of a septet vagina, when a blade is inserted in either side.



Advantages:

1. Easy to introduce.
2. Self-retaining.
3. Can be adjusted to the size of the vagina.

Disadvantages:

1. It hides the anterior and posterior vaginal walls; however, this disadvantage is overcome by inspection of the vaginal walls during its gradual withdrawal.
2. It doesn't offer complete protection of vaginal walls during cauterization of the cervix.

(2) Sim's vaginal speculum

Indications:

1. Expose the anterior vaginal wall especially in cases of vesico-vaginal fistula, both for diagnosis (prolapse) and for operative repair (episotomy).
2. It can also be of value to insert a vaginal pack.



Advantages:

1. Gives an excellent view of the anterior vaginal wall.
2. The grooved blade directs the blood or urine outside when used in the lithotomic position, and provides a space for operative work.

Disadvantages:

1. Assistance is required especially when used to expose the cervix or during surgical procedures, as it is not self-retaining.
2. In the presence of a large cystocele, exposure of the cervix is often difficult.

(3) Auvar'd's self-retaining vaginal speculum

Indications: most operations performed per vagina.

Advantages:

1. It is self-retaining.
2. It gives good exposure of the anterior vaginal wall and cervix during operations



Disadvantages:

1. It may tear, bruise or overstretch the soft tissues of the perineum and posterior vaginal wall.
2. It is difficult to use in nulliparae
3. It hides the posterior vaginal wall.



Urinary Instruments

Metal Urinary Catheter

These are of two forms: the straight and the curved (S-shaped)



Indications:

- In the 1st stage of labor to prevent uterine inertia
- In the 3rd stage of labor to prevent retention of the placenta and guard against post-partum hemorrhage
- Before any gynecological or obstetrics examination
- For the diagnosis of urinary fistula
- Vesicle calculus (click sound)



Complication

- Introduction of sepsis
- False passage in the urethra or perforation of bladder wall
- Urethral shock and fever

Hodge Pessary

Indications:

1. Symptomatic uterine prolapsed
2. Pelvic support defects
3. Vaginal Prolepses



Contraindications:

1. Active infections of the pelvis or vagina.
2. Patients who are noncompliant or unlikely to follow up.
3. Allergy to the product.

Follow Up:

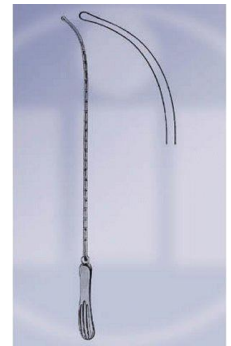After the initial fitting of the pessary, the patient should be followed-up within a few days so that the physician can recheck the fit. The pessary should be removed so that the vagina can be examined for irritation, pressure sores or allergic reaction. Having to change the size of the pessary at least once after the initial fitting is not uncommon.

The patient should then be instructed to follow-up within one to two weeks for another examination, after which time the examinations can be spaced to every two to three months. In the motivated patient who is able to demonstrate effective removal, insertion and care of the pessary, these examinations may be spaced further at the discretion of the physician.

At each follow-up examination, the pessary should be removed and cleaned with soap and water while the vagina is inspected for erosions, pressure necrosis or allergic reaction. If inspection of the pessary reveals cracking or other defects, it should be replaced. The patient who is using a pessary should be considered to be under the care of the person who placed it for the duration of its use. Pessaries should never be placed in elderly, debilitated patients without excellent follow-up.

Sims Uterine Sound

- Graduated in centimeters or in inches.
- Malleable (can be bent and twisted easily- قابل للطي- لين، مرن، قابل للطي)
- Corrugated handle (during insertion they should face upwards)
- The whole diameter = 3mm,
- The diameter of the knob = 4 mm



Indications:

- Measures the length of the cervical canal, the uterine body and that of the whole uterus (before D&C and after insertion of an IUCD)
- To determine the direction of the uterus. (RVF: the corrugations on the handle will face downward after it was facing upwards)
- To differentiate uterine inversion from a submucous fibroid.
- Differentiate between a uterine polyp (can go around it) and a cervical poly (cant go around it)
- It determines the relation of the uterus to any pelvic mass.
- It differentiate true from pseudoprolapse (congenital elongation of the cervix). The sound is inserted into the lateral vaginal fornix and its relation to the ischial spines is evaluated.
- To diagnose vesico-vaginal fistula. The sound is passed through the fistulous opening in the vagina where a click is elicited against a metal catheter in the urinary bladder.

- Missed loop: insert the uterine sound then do X-ray, if the IUCD is far away from the sound → The IUCD has perforated out of the uterus. If the sound is close to the IUCD → the IUCD is inside the uterus
- To diagnose a bicornuate uterus, a uterus septus, and a uterus subseptus (uterine anomalies).
- Cervical stenosis
- 1^o dysmenorrhea
- Probe test of friability for cancer cervix (Kroback's test).

How to Use:

1. The uterine sound is inserted through the cervix
2. The first resistance is the internal OS → length of the cervical canal
3. The second resistance is the uterine fundus → length of the uterus + the cervix



Complications:

1. Disturbance of an undiagnosed pregnancy
2. Perforation of the cervix or body of the uterus
3. Ascending infection

Contraindications:

1. Genital infections
2. Suspicion of pregnancy
3. Soft uterus (malignancy, infection, molar pregnancy).

Hegar's Uterine Dilators

	
<p>Double-ended Hegar Uterine Dilator 3-18mm</p>	<p>Single Ended Hegar's Uterine Dilator.</p>

- They are used to gradually dilate the cervix
- They can be single or double ended
- Uniform thickness

- There are 15 Hegar dilators, graduated by a number written on them ranging from 0-14 which corresponds to the thickness in millimeters.
- The tip is slightly curved.
- They are held between the index and the thumb at a level less than the uterine length

Indications for cervical dilatation:

A) Diagnostic

1. Incompetent internal os. The passage of dilator no. 8 through the internal os without causing pain or meeting with resistance signifies incompetence.
2. Before the exploration of the uterine cavity for diagnosis of intrauterine lesions and septa.
3. As a preliminary step to diagnostic curettage of the endometrium.
4. Prior to insufflations or hysterosalpingography in cases with a narrow external os.
5. For diagnosis of spasmodic dysmenorrhea; the passage of no. 4 Hegar's dilator causes severe pain when it reaches the internal os.

B) Therapeutic

1. Dysmenorrhea: the idea is that dilatation (at least to No.14) act as a local sympathectomy by cutting the nerves at the internal os.
2. Spasmodic amenorrhea
3. Drainage of hematometra or pyometra.
4. In some cases of sterility with a pin hole external os.
5. Stenosis of the cervix, e.g. post-operative or post-cauterisation.
6. Cervical abortion.

C) As a step in the course of other operations

1. Preliminary to curettage or evacuation.
2. A step in the management of vesicular mole and certain types of abortions: (a) Missed abortion.
(b) Therapeutic abortion.
3. Vaginal hysterotomy.
4. Removal of fibroid or endometrial polyps.
5. Cervical conization, amputation, Fothergill's operation and trachelorrhaphy.
6. Before insertion or removal of certain contraceptive devices.

Degree of dilatation: *The degree of dilatation is governed by the indication:*

1. For curettage dilate to no. 10-14
2. For dysmenorrhea dilate to 14-16.
3. For finger exploration and digital separation of a conceptus dilate to no. 18-22 (varies according to the diameter of the operator's finger).

Contraindications:

1. Genital infections.
2. Normally pregnant uterus.




Complications

1. Perforation of the cervix or body of the uterus. It is sequel to forceful manipulations in a wrong direction. Pregnancy, vesicular mole and malignancy increase the chances for perforation because of the soft and friable uterine wall.
2. Lacerations of the cervix.
3. Cervical incompetence and habitual abortion. (most common)
4. Ascending infection (cervicitis, endometritis, salpingitis, peritonitis and parametritis)
5. Endometriosis results from the piston like action of the dilator which pushes endometrial fragments through the tubal osia.

Vulsellum Forceps

Types:

1. Single toothed (bullet forceps) Tenaculum
2. Double toothed (Fenton's bull-dog vulsellum or the lion's forceps)
3. Multiple toothed vulsellum (Tenaculum)

		
<p>Tenaculum</p>	<p>Double toothed vulsellum</p>	<p>Multiple toothed vulsellum</p>

Indications:

1. Grasping of the cervix
 - (a) During minor office practice manipulations, e.g. insertion of a uterine sound, or an IUCD in difficult cases and during insufflation and hysterosalpingography.
 - (b) To estimate the degree of uterine descent in cases of prolapse by pulling on the cervix downwards and observing the level to which it reaches
 - (c) To evaluate the mobility of the uterus; this may be limited in fibroid tumors.
 - (d) During vaginal operations, e.g. dilatation and curettage and repair of prolapse.
 - (e) To help correction of RVF by pulling backwards on the anterior lip of the cervix.
2. To grasp a prolapsed submucous myoma during a vaginal myomectomy.
3. During operation of hysterectomy it can be used to hold the cervical stump after the removal of the uterine body in subtotal hysterectomy.

Contraindications:

- The soft pregnant cervix,
- Infections,
- Suspicious malignancy of the cervix.

Complications:

1. Lacerations of the cervix.
 2. Infections
 3. Bleeding from the site of the bite of the teeth of the vulsellum
-

Ring and sponge forceps

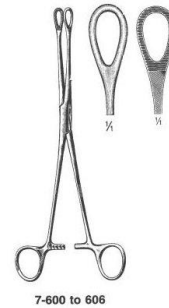
Both possess a handle, a lock, a shank and 2 jaws at the tip, the jaws are either smooth or serrated, either rounded or oval in shape

Indications:

1. To grasp the soft lips of the cervix in pregnancy, e.g. during evacuation
2. To evacuate a pregnant uterus per vagina
3. It is used for removing corporeal and cervical polypi.
4. Can be used as a sponge carrier



Ring Forceps



Sponge forceps

Ovum forceps

- It is a miniature of the obstetric forceps
- Each branch has a handle, a shank and a blade; the two branches are attached by a screw joint and has no lock
- It is used to remove an intact separated ovum; the cervix in these cases needs to be dilated to no 18 Hegar's and it is also used to evacuate the uterine content after D&C.



Single-ended corrugated sharp or blunt Uterine Curettes

- Each curette consists of 3 parts, the handle, the shank and the curetting end.
- The handle is corrugated on the aspect which corresponds to the direction of the bend at the tip. It can be either on the side (single-ended) or in the middle (double-ended).
- The shank is malleable & is hollow in the flushing variety to convey irrigating fluids which stimulates the uterus to contract and can also be used to deliver antiseptic material.
- The curetting end may be sharp or blunt, and some are spoon shaped.
- Some types have a curetting end on either tip (double-ended) with the handle in the middle.

I. Diagnostic curettage:

A) Bleeding

1. Dysfunctional uterine bleeding.
2. Symmetrically enlarged uterus.
3. Suspected uterine malignancy.
4. Secondary post-partum and post-abortive bleeding.
5. Cervical adenomatous polypi.
6. Doubtful extrauterine pregnancy to exclude the presence of chorionic villi.
7. Suspected TB and Bilharzia.

B) Amenorrhea


1. Atrophic endometrium.
2. Polycystic ovarian syndrome (Stein-Leventhal syndrome).
3. TB endometrium

C) Sterility

1. Anovulation.
2. TB endometrium.
3. Non-responsive endometrium.
4. Hormonal function of the ovaries

II. Therapeutic curettage:

- 1) For temporary or permanent cure of non-malignant uterine bleeding e.g. metropathia hemorrhagica and other types of functional bleeding and secondary post-partum and post-abortive bleeding.
- 2) Membranous dysmenorrhea.
- 3) Removal of endometrial polypi.



- 4) In the management of some abortions (inevitable, incomplete, missed, cervical and therapeutic abortions) to ensure complete removal of the conceptus and decidua.
- 5) Vesicular mole.
- 6) To remove unhealthy endometrium during operation, e.g. Manchester (Fothergill's) operation and myomectomy.

The operation of curettage:

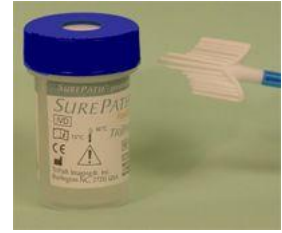- Patient should be anesthetized and lying in the lithotomy position.
- Empty bladder and rectum.
- Dilate the cervix to No. 12 hegar's.
- The curette is introduced till the fundus and then by downward thrusts the endometrium is scraped systematically so that all walls is scraped, including the cornua and fundus.
- The curette of an area is considered complete when a gritty sensation is felt or heard.
- In cases of abortion and vesicular mole it is sometimes advisable to do curettage while an I.V. drip of syntocinon is continuously running to minimize the danger of proliferation.

Complications:

1. Sepsis: Introduction of infection into the uterine cavity leads to acute endometritis, salpingitis and /or peritonitis.
2. Perforation of the uterus: This is the most common complication occurring as a result of improper and too vigorous handling of the curette or aggravation of a minor laceration done by the dilator at the internal os. It is particularly liable to occur in malignant conditions, infections, vesicular mole and abortion.
3. Permanent amenorrhea and sterility result from vigorous over curettage removing the basal layer of the endometrium and intrauterine adhesions (Asherman's syndrome or Endometrial synechiae)
4. Excessive bleeding may occur during curettage in cases of carcinoma of the uterine body.
5. The use of a flushing curette may push endometrial tissue through the Fallopian tubes, leading to pelvic endometriosis or peritonitis.

Cervical Scrapers (wooden spatula) & Roller brush

- For endocervical sampling
- This is a wooden spatula for “surface biopsy” which provides a selective cytology technique (pap smear).
- It is neither a true biopsy nor a smear, but a scraping from the squamo-columnar junction of the cervix.
- The irregularly shaped end of the scraper is used with its tip in the external os; with a rotatory movement the entire area of the squamo-columnar junction is scraped. The other end is used for scraping the surface of the edge of suspicious erosion.
- *Pointed end for Nulliparous & other for muliparous*
- It is diagnos **Cervical cancer**, caused by Human papilloma viruses (HPV)



Risk factors for cervical cancer:

1. Old age.
2. White women.
3. Early sexual active.
4. Multiple sexual partners.
5. Smoking.

	
<p>Ayer's Cervical Scraper (wooden spatula)</p>	<p>Aylesbury's Cervical Scraper (wooden spatula)</p>

II. Obstetric Instruments




Pre-requests:

- Cephalic presentation (piper forceps is used for breech)
- Head is engaged 0- 2
- Fully dilated bladder
- Maternal pelvis adequacy
- Ruptured membranes
- Empty bladder
- Episiotomy
- Anesthesia

The Obstetric Forceps

Types of forceps

1. Short curved Wrigley's obstetric forceps.
2. Long curved Simpson's obstetric forceps
3. Long straight Kielland's obstetric forceps.

		
Long curved Simpson's obstetric forceps	Short curved Wrigley's obstetric forceps	Long straight Kielland's obstetric forceps

Types of forceps deliveries:

- High forceps:
 - This means forceps applied to a high head (non-engaged head).
 - It is not done any more.
- Mid-forceps
 - The fetal head is engaged but the biparietal diameter is still above the ischial spine level.
 - The lowest bony part of the head is felt below the ischial spines.

- Low forceps (outlet forceps)
 - The biggest transverse diameter (biparietal) has passed the ischial spine level.
 - The lowest bony part of the head has already reached the perineum and is visible either during or between contractions.

Parts:

It consists of 2 branches, right and left. Each branch is made of:

1. A blade:
 - Each blade has a cephalic curve, a pelvic curve, and a fenestrum.
 - The cephalic curve: medial curved aspect of each blade.
 - The pelvic curve: This curve conforms with the curve of the birth canal.
 - The fenestrum makes the forceps lighter in weight, offers a firm grip over the head and avoids slipping and it minimizes injury of the head.
 2. A shank: This is the part of the forceps intervening between the blade and the handles.
 3. A handle: The handles cross to the opposite side of the blade so that the left handle is held by the left hand and is put at the left side of the birth canal and the right handle is held by the right hand and is put at the right side of the birth canal.
- The branches are joined by a lock located at the junction between the shank and the handles
 - The left blade is inserted first followed by the right blade, because the lock will only lock if the right branch was placed on top of the left branch.

Direction of pull: Downwards, forwards

Types of forceps Application:

- (A) Cephalic application:
 - One blade on either side of the head along the mento-vertical diameter.
 - The safety margin that is permissible extends from the zygoma (العظم الوجني) anteriorly to the mastoid process posteriorly.
- (B) Pelvic application
 - The hand is applied inside the birth canal under the blade to prevent maternal tissue injury.
 - The left blade is inserted first followed by the right blade.
 - A safety margin within the pelvis extends from the sacroiliac joint to the iliopectineal eminence.

Kielland's Obstetric forceps:

- Long, straight (very slight) pelvic curve.
- It has a backward or a perineal curve on the posterior aspect.
- Overlapping shanks (upper and lower)
- A sliding lock allowing application to asynclitic heads.
- Light weight
- Main indication: *rotation of the head and for application to asynclitic heads.*
- Disadvantages: an unstable lock predisposes to cervical and vaginal lacerations

Action of the forceps:

1. Traction on the head (the main action).
2. Rotation of the head.
3. Compression of the head (this should be minimal to avoid intracranial hemorrhage).
4. Stimulation of uterine action.
5. Dilatation of the vulva.
6. One blade can be utilized to dislodge the head out of a lower segment cesarean section incision.

Indications of forceps delivery:

1. Maternal

- (A) Threatened dangers to the mother (prophylactic forceps):
- Toxemia of pregnancy (pre-eclampsia and eclampsia).
 - Previous cesarean section
 - Weakness in the abdominal wall (hernias and a history of a recent abdominal operation).
 - Associated disease, e.g. Diabetes, heart disease, lung disease, chronic nephritis, hypertension, etc.
- (B) Rigid pelvic floor and perineum
- (C) Uterine inertia
- (D) Maternal distress

2. Fetal

- (A) Threatened dangers to the fetus (prophylactic forceps), as in the case of prolapse of a pulsating umbilical cord
- (B) Abnormal presentations and positions: occipitoposterior, deep transverse arrest, face presentation, after-coming head.
- (C) Large sized fetal head
- (D) Fetal distress

3. Prolonged second stage of labor

(A) Over 1-2 hours in multiparae or 2-3 hours in primigravidae, depending on the uterine activity.

(B) When the head is on the perineum for one hour or more

Conditions to be fulfilled before forceps application (pre-requiites):

1. A deliverable cephalic presentation.
2. Engaged head
3. Empty bladder and rectum. (*Dangers of a full bladder: genito-urinary fistula, rupture of the bladder, failed forceps, atonic post-partum hemorrhage, and stress incontinence*).
4. Fully dilated cervix. *Otherwise it might cause trauma to the cervix causing cervical tears or uterine prolapse (remote complication).*
5. Use of anesthesia.
 - *Allows proper application and extraction and avoids the development of obstetric shock.*
 - *It can be either: pudendal nerve block, low spinal or saddle block, epidural or general anesthesia.*
6. Some uterine contractions must be present. *Delivery with the obstetric forceps in the complete absence of contractions is followed by severe post-partum hemorrhage.*
7. Ruptured membranes.
8. Episiotomy. *Not always done, it is mostly indicated for primigravidae with rigid perineum*

Complications:**(A) Fetal**

1. Asphyxia (intracranial injury, aspiration, cord compression and anesthesia)
2. Fracture of the skull bones
3. Intracranial hemorrhage
4. Nerve lesions: Bell's palsy, Brachial plexus injury.
5. Lacerations and contusions of the scalp and cephalhematoma which might get infected and forms an abscess.

(B) Maternal

1. Risks of anesthesia.
2. Traumatic lesions of the lower uterine segment, cervix, vagina and perineum.
3. Sepsis
4. Obstetric shock

5. Bone injuries:
 - Separation of the symphysis.
 - Dislocation of the sacro-iliac joint; this may be followed by a waddling gait, and severe low backache.
 - Fracture of the coccyx or its dislocation from the lower end of the sacrum.
6. Post-partum hemorrhage (traumatic, or atonic if delivery is completed in the absence of labor pains).
7. Vesico-vaginal fistula and stress incontinence. The former results either from direct trauma to a full bladder during application or extraction, or from ischemic effects of prolonged compression in protracted labor.

Forceps Operation in occipito-posterior and transverse positions:


1. Manual rotation
 - (A) Manual rotation of the head to bring the occiput anteriorly:
 - This is done by the right hand for left positions and vice versa.
 - The other hand is simultaneously placed on the abdomen to pull the back of the child towards the midline.
 - It is followed by forceps delivery on the anteriorly rotated head.
 - (B) Manual rotation of the head to bring the occiput posteriorly:
 - It is only done when attempts at anterior rotation fail.
 - It is followed by forceps delivery as face to pubis.
 2. Forceps rotation
 - (A) Scanzoni's double application maneuver:
 - It is done using the long curved obstetric curve as a rotator and an extractor.
 - After rotation of the head, the pelvic curve of the forceps will be directed backwards.
 - The forceps must be removed and reapplied with the pelvic curve of the instrument directed forwards.
 - (B) Kielland's forceps:
 - It is applied once with no need of reapplication because it is a long almost straight forceps.
-

Green Armytage forceps

- It is a long forceps with flattened serrated tips that serves as a holding and haemostatic instrument.
- It is usually used during the operation of lower uterine segment cesarean section to hold the flaps of the uterine incision to control bleeding from the edges and to help their suturing.



The Vacuum Extractor or Ventouse



Indications:

- All the indications of forceps delivery except the face (can cause serious eye damage) and after coming head. The ventouse is not helpful when a rapid delivery is aimed e.g. In fetal distress
- To increase flexion in deflexed heads & to help forward rotation of the occiput in occipito posterior & deep transverse arrest.
- To assist completion of cervical dilatation; the cervix should be at least 3/4 dilated or more.
- It can be used to control bleeding by traction on the head in placenta previa.
- In cord prolapse it serves to prevent recurrence after its successful replacement
- It can be utilized to remove the head out of a lower uterine segment cesarean section
- It May be of help to correct inertia in the first stage by pulling the head to be well applied to the lower uterine segment & cervix.

Contraindication:

- Face, breech, & transverse presentation of the after coming head.
- Premature babies.
- Moderate or severe cephalo-pelvic disproportion.
- Fetal & maternal distress necessitating a rapid delivery.

Complications:

- Risk of cervical incompetence.
- Vaginal laceration from entrapment of vaginal mucosa between the suction cup and fetal head.
- Fetal skull injuries: cephalohematoma, intracranial hemorrhage & cerebral irritation, subaponeurotic hemorrhage and scalp lacerations, necrosis & alopecia.
- Longer delivery time.

Method:

- Use the largest possible cup.
- Pressure is gradually reduced (in about 8 min.) to reach a max. Vacuum of 0.8 kg/cm² (600 mmHg).
- Allows the formation of a caput inside the cup to fill it.
- It shouldn't be used for longer than 40 min (scalp necrosis & alopecia).

Advantage over the forceps:

[Mother]

- Less risk of anesthesia, sepsis & trauma
- Helps cervical dilatation & +ve uterine contractions
- It doesn't occupy space adjacent to the fetal head → less trauma and smaller episiotomy.
- Can be applied if the cervix is not fully dilated.

[Fetus]

- Corrects malattitudes of the fetal head
 - Helps rotation of the head
-

Amnihook



Indication:

1. To rupture the amniotic membrane with minimal risk of trauma to foetus or mother.
2. Use for Amniotomy.

After the fetus is engaged and it has been determined that the patient is in true labour, then the membranes may be ruptured with the Amnihook.

Contraindication:

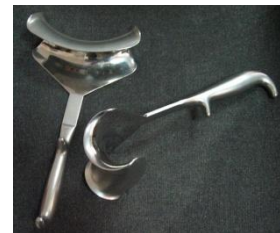1. Cephalopelvic disproportion, unless slight, including the nullipara with a high head.
2. Abnormal presentation (with the possible exception of face or breech).
3. Unstable lie - risk of cord prolapse.
4. Foetal distress - caesarean section would be indicated.
5. Pplacenta praevia.
6. Cord presentation.
7. Vasa praevia.
8. Invasive carcinoma of the cervix.

For diagnosis rupture of membrane:

1. **Nitrazine test:** acts by pH and turn from yellow to blue in alkaline media. Blood, semen, urin & infection give false +ve test.
2. **Ferning test:** seen by microscope .

Doyn or doin retractor

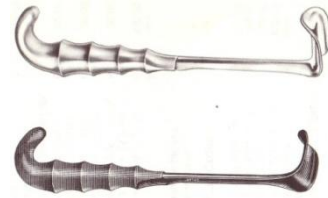
To retract the Urinary Bladder



Skin Retractors



Retractor with weight



Fetal scalp electrode

Instrument used to monitor the baby's heartbeat while still in the uterus. This device is placed just under the skin of the baby's scalp



Pap smear kit

Which consist of spatula, fixative, slide & swab



Pipelle

For endometrial sampling. It works by suctioning i.e. -ve pressure

Veress needle & Laparoscope



Indications:

1. To make the incision of laparoscopy
2. For Co₂ inflation of the abdomen prior laparoscope
3. Laparoscope: diagnostic (infertility & ectopic pregnancy) & therapeutic (adhenolysis)

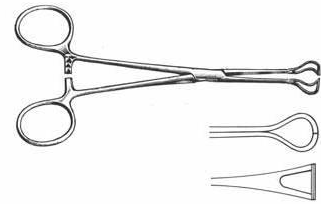
Complication:

1. Pneumoperitoneum .
2. Injury to a hollow viscus.
3. Injury to vessels in the abdominal wall.
4. Damage to other organs.
5. Pelvic inflammatory disease.
6. Cervical laceration.
7. Uterine perforation.
8. Shoulder pain.




Babcock forceps

To hold a short length of intestine without compressing it



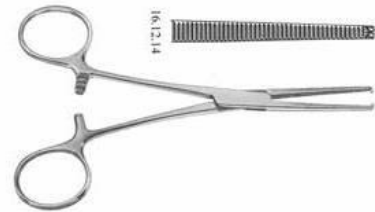Allis forceps

Used to forcibly grasp or retract tissues or structures



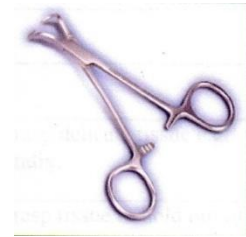Kocher forceps

For controlling bleeding in surgery, having serrated blades with **interlocking** teeth at the tips

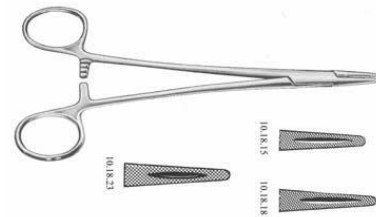


Towel clip

To hold drapes in place to retract tissue

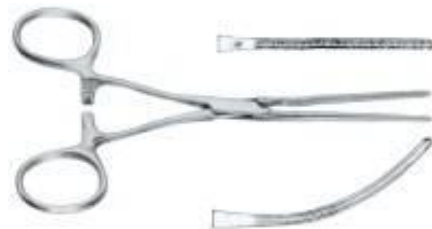

Needle holder



Artery forceps - straight & curved -

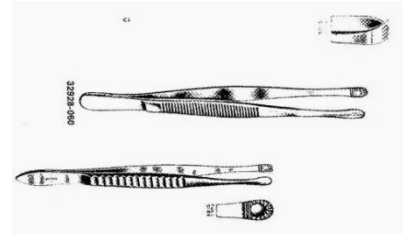
To clip the cord or a bleeding artery



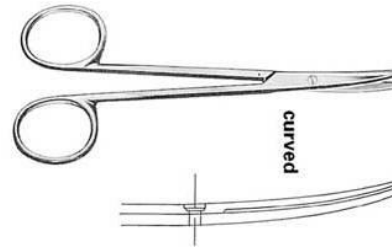
Tissue forceps

Toothed: for holding thick structures e.g. skin, it is traumatic

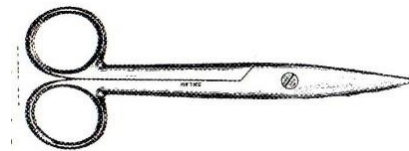
Not-toothed: for holding fragile structures e.g. vagina. It is less traumatic



Dissecting scissors



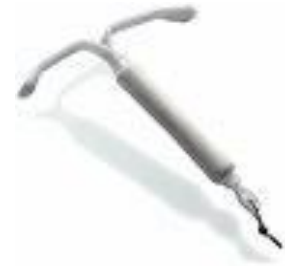Cutting scissors



IUCD

Mechanism of action:

The primary mechanism of action of the IUD is spermicidal/ovicidal. It is prevent fertilization primarily by interfering with the ability of sperm to survive and to ascend the fallopian tubes, where fertilization occurs. Having a foreign body in the uterus, such as an IUD, causes both anatomical and biochemical changes that appear to be toxic to sperm. When a foreign body is in the uterus, the endometrium reacts by releasing white blood cells, enzymes and prostaglandins; and these reactions of the endometrium appear to prevent sperm from reaching the fallopian tubes. In addition, copper-bearing IUDs release copper ions into the fluids of the uterus and the fallopian tubes, enhancing the debilitating effect on sperm.



Side effects:

- Mood changes
- Acne
- Headaches
- Breast tenderness
- Pelvic pain
- Cramping (copper IUD)
- Increased bleeding during menstruation (copper IUD)
- Nausea

Advantages:

1. Allows sexual spontaneity.
2. Requires no daily attention.
3. Immediately effective.
4. Long-lasting.
5. Not messy.

Disadvantages:

1. Does not protect against sexually transmitted infections, including HIV/AIDS.
2. Insertion and removal require clinic visits.
3. Can be expelled.
4. Can cause more difficult menstrual periods.
5. Possible risk to future fertility.

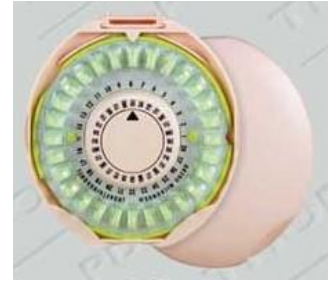Contraindications:

1. Postpartum between 48 hours and 4 weeks (increased IUD expulsion rate with delayed postpartum insertion).
2. Benign gestational trophoblastic disease.
3. Ovarian cancer.
4. Very high individual likelihood of exposure to gonorrhea or chlamydial STIs.
5. AIDS (unless clinically well on anti-retroviral therapy).
6. Pregnancy.
7. Postpartum puerperal sepsis.
8. Immediately post-septic abortion.
9. Before evaluation of unexplained vaginal bleeding suspected of being a serious condition.
10. Malignant gestational trophoblastic disease.
11. Cervical cancer (awaiting treatment).
12. Endometrial cancer.
13. Distortions of the uterine cavity by uterine fibroids or anatomical abnormalities.
14. Current PID.
15. Current purulent cervicitis, chlamydial infection, or gonorrheal STIs.
16. Known pelvic tuberculosis.

Progestin-Only Contraceptives

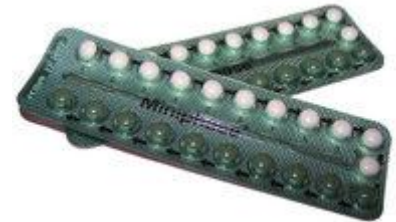Mechanisms of action:

- Inhibition of ovulation
- Prevention of sperm penetration by thickening and decreasing the quantity of cervical mucus
- Endometrial atrophy



Advantages:

- No estrogen
- Reversible
- Amenorrhea or scanty bleeding
- Improvement in dysmenorrhea, menorrhagia, PMS, endometriosis symptoms
- Decreased risk of endometrial or ovarian cancer
- Decreased risk of PID
- Compatible with breast-feeding
- Best choice for Cardiac Pt.



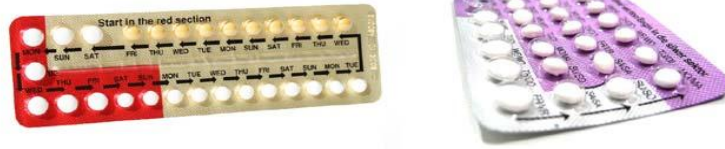Disadvantages:

- Menstrual cycle disturbances
- Weight gain
- Depression
- Lack of protection against STIs

Contraindications:

1. Known or suspected pregnancy
2. Unexplained vaginal bleeding
3. Breast cancer
4. Medication that cause progestins to be metabolized more rapidly:
 - Anti-seizure medications: phenytoin, phenobarbital, carbamazepine, primidone, phenbutazone, and
 - Antibiotics: rifampin/rifampicine
5. Active thrombophlebitis or pulmonary emboli

Combination Contraceptives (Estrogen & Progestin)



Mechanisms of action:

- Suppression of ovulation
- Thickening of cervical mucus
- Thinning of endometrium
- Slowing of tubal and endometrial motility

Advantages:

- Highly effective in preventing pregnancy when taken correctly
- Not related to coitus
- Rapid return to fertility after discontinuation
- Very safe when prescribed for appropriate users
- Can be used throughout the reproductive years

Health benefit:

- Fewer pregnancies = fewer maternal deaths
- Reduction in risk of ectopic pregnancy
- Decrease in dysmenorrhea
- Decrease in menorrhagia
- Reduction in PMS symptoms
- Elimination of Mittelschmerz
- Decreased anovulatory bleeding
- Fewer ovarian cyst problems
- Endometrial and ovarian cancer risk reduction
- Decreased risk of benign breast conditions
- Suppression of endometriosis
- Improvement of androgen-sensitivity or androgen-excess conditions (such as PCOS)
- Improvement in hot flashes and hormonal fluctuation symptoms in perimenopausal women

Disadvantages:

- Must be taken consistently and correctly to be effective
- Storage, access, lack of privacy
- Can interfere with lactation
- No protection against STIs
- Common side effects include:
 - Breast tenderness
 - Decrease libido
 - Skin hyper pigmentation
 - Nausea & Vomiting
 - Headache
 - Weight gain

Complications:

- Venous thromboembolism.
- Myocardial infarction and stroke.
- Hypertension.

Contraindications:

- Personal history of thrombosis; known clotting disorder (factor V Leiden mutation, etc.).
- Personal history of stroke or MI.
- Labile hypertension.
- Estrogen-sensitive malignancy (such as breast CA).
- Active liver disease.
- Migraines with focal neurologic symptoms.

The End

